

Soft Tissue Contraction in Body Contouring With Radiofrequency-Assisted Liposuction: A Treatment Gap Solution

Spero J. Theodorou, MD; Daniel Del Vecchio, MD; and Christopher T. Chia, MD

Aesthetic Surgery Journal
2018, Vol 38(S2) S74–S83
© 2018 The American Society for
Aesthetic Plastic Surgery, Inc.
Reprints and permission:
journals.permissions@oup.com
DOI: 10.1093/asj/sjy037
www.aestheticsurgeryjournal.com

OXFORD
UNIVERSITY PRESS

Abstract

Radiofrequency-assisted liposuction is a relatively new concept in energy-assisted body contouring techniques and has received instrument approval. This supplemental article reviews the clinical application of electromagnetic energy via the BodyTite (InMode Corporation, Toronto, Canada) device on soft tissues during suction lipectomy, its effect on soft tissue contraction, and its use in aesthetic body contouring in various clinical scenarios.

Editorial Decision date: January 31, 2018.

Liposuction is the most commonly performed aesthetic plastic surgery operation performed worldwide.¹ The continuous rise of obesity in developed industrialized countries has become both an aesthetic concern as well as an increasing burden to the healthcare system in nearly all developed countries. The combination of this trend along with the phenomenon of social media has created a demographic shift towards younger patients seeking body contouring improvements. With the advent of the “selfie,” the average millennial will take 25,000 of these images in their lifetime² and thus are more aware of how they present to others than in any preceding generation. This does not mean that older patients are not seeking plastic surgery and body contouring procedures. On the contrary, the adoption of noninvasive and minimally invasive procedures in this younger population with its rising popularity has brought body contouring to the forefront and has become more than just an adjunct procedure after having children for middle aged females. An improved understanding of aesthetic concepts, fluid dynamics, alternative anesthetic options such as local anesthesia, and technical advancements have made the operation safer and more accessible as well.³ As a result, patient expectations have accordingly increased along with these refinements in body contouring procedures. Despite recent advances in this field, finding

a solution to tighten skin while removing fat remains elusive. Ideally, fat removal for volume reduction would be coupled with contraction of the overlying soft tissue envelope and skin. In addition, it would be done in an accredited office-based setting under local anesthesia with minimal bruising and swelling followed by a fast recovery with minimal to no downtime from normal daily activities.

BACKGROUND

Radiofrequency (RF) thermally induced contraction of collagen is well known and has been used in a variety of fields ranging from ophthalmology to varicose vein treatment and to soft tissue tightening. In order for neocollagenesis

Drs Theodorou and Chia are Clinical Assistant Professors of Surgery, Donald and Barbara Zucker School of Medicine, Hofstra University; and Assistant Clinical Attendings, Manhattan Eye, Ear & Throat Hospital, New York, NY. Dr Del Vecchio is an Instructor in Surgery, Department of Plastic Surgery, Massachusetts General Hospital, Boston, MA.

Corresponding Author:

Dr Christopher T. Chia, 128 Central Park South, New York, NY 10019, USA.
E-mail: christophertchia@gmail.com; Twitter: @body_sculpt

Table 1. Patient Information

No. of patients	312
Gender	
Female	265 (84.9%)
Male	47 (15.1%)
Average age, years	31.4
Average BMI, kg/m ²	23.2

BMI, body mass index.

to occur, the dermal and soft tissue components need to be heated to a range of 60 to 80°C³ and approximately 40 to 42°C on the skin surface.⁴ There is an optimal temperature range where restructuring of these fibers occurs as opposed to tissue destruction and coagulation. Whereas multiple modalities such as laser and ultrasound have been purported to be effective,⁵⁻⁸ we present our experience with the BodyTite (InMode Corporation, Toronto, Canada) device (Table 1), where electromagnetic radiation is applied directly to the soft tissues. Radiofrequency energy is transmitted from a generator device platform (Figure 1) to a directional handpiece (Figure 2). An internal probe is located in the subcutaneous adipose layer and the external probe makes contact with the skin. All the soft tissue in between the electrodes is treated with the RF. The continuous RF is applied with a continuous movement of the hand piece, thus delivering a uniform energy to a large area. Efficient heating of the treated soft tissue is achieved with a high degree of safety that restricts the internal and external temperature. This allows for efficient energy deposition which shortens operative time when compared to other modalities attempting to heat the same volume of tissue to a target temperature. These characteristics of this particular RF energy platform have led to its use in the field of body contouring where tissue laxity is a challenge. On volumetric analysis, soft tissue linear contraction, described as the “fibro-septal network” response to RF energy, has been described as high as 47% with thickening of the collagen matrix on histological examination of skin biopsies six months postoperatively. In the same study, Blugerman et al reached an average local linear contraction of 31% that is statistically significantly higher than that reported with other energy-emitting liposuction technologies.⁹

The ability of RF to affect significant contraction of the soft tissue increases the potential patient population who may not have skin laxity severe enough to warrant a standard excisional operation but will likely have a poor aesthetic outcome with liposuction alone due to overlying skin elasticity deficiency. There is a large number of these “in between” patients in this “gap” category that their clinical picture presents as “not bad enough for an excisional procedure and not good enough for liposuction.” Specifically,



Figure 1. Radiofrequency energy generator platform (InMode Corp., Toronto, Canada).

areas of the body described as zones of nonadherence¹⁰ such as the arms, neck, and medial thighs may be amenable to radiofrequency-assisted liposuction (RFAL) for satisfactory contouring who otherwise would be turned away with liposuction alone by the judicious surgeon. The RFAL technology, being more effective and directed at fat resection, can be achieved with an increased margin of safety since the skin can be anticipated to retract more than with manual suction-assisted lipectomy (SAL) alone.⁵ In a study comparing aggressive superficial liposuction with RFAL in arm sculpting,¹¹ the results were suggestive that results were superior with RF (although the sample size was too small to reach statistical significance.) It has been noted

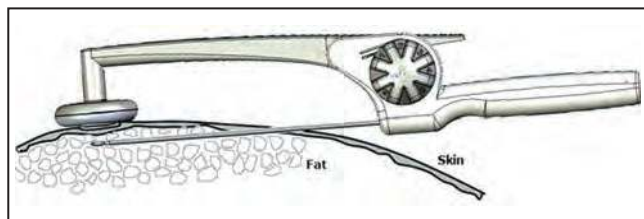


Figure 2. BodyTite handpiece (InMode Corp., Toronto, Canada).

that even in experienced hands that rate of complications, especially of contour deformities, with superficial liposuction is much higher.¹² In our experience, we found RFAL can achieve consistent and reproducible results with excellent soft tissue contraction but without the complication rates of aggressive, superficial liposuction.

DEVICE

The hand-held hand piece transmits the RF energy from the generator platform (BodyTite, Toronto Canada) between two electrodes; the internal electrode is placed in the subcutaneous adipose layer and the external electrode is in contact with the skin. The device received FDA approval in 2016 with the indication of electrocoagulation of soft tissues. The RF energy alternates between the internal electrode and the external electrode through the skin layers. RF density is higher around the smaller internal electrode than around the larger external one. In this arrangement, heating is selective, with lower temperature on the skin surface for safety while temperatures reached are higher inside the fat layer. This also achieves highly efficient and controlled energy deposition to only the tissue in between the electrodes and obviates the need for a grounding pad (Figure 3). The RF energy transmitted between the two electrodes induces coagulates of fat and contraction of the fibroseptal network (FSN), causing retraction of the soft tissue flap through later neocollagenesis.^{5,9} The device is measuring in real time the amount of energy deposited during the treatment as well as the external and internal temperatures of the tissue (Figure 4), as well as tissue impedance. The goal for the external temperature is to reach 40 to 42°C. Once the end point of 40 to 42°C surface temperature is reached, RF is disabled and the treatment is terminated. Once the tightening portion of the treatment is finished, this is followed by suction-assisted lipectomy for contouring purposes, if necessary. For smaller areas of the face (FaceTite) and for soft tissue tightening where fat removal is not required, liposuction is not performed. It is noted, however, that in areas of significant heat deposition outside of the face and possibly neck, where the volume of the fat coagulated by the device is anticipated to be > 100 mL, it is important to remove the liquefied end products with a small amount of

liposuction even though contouring is not required. This is done to remove the heated fluids that otherwise would pool in the operated areas and increase the risk of subsequent seroma formation and fat necrosis. This is due to the considerable amount of residual heat in both the treated soft tissues and tumescent fluid that remains after the treatment for that area has been completed.

Significant safety features have been included into the device platform due to the considerable amount of energy that is applied to the tissues in between the electrodes to minimize the risk of thermal injury. Real-time impedance and temperature monitoring is provided by both the internal and external electrodes so that goal temperatures are achieved and maintained for the time required. Once the goal temperature is achieved, the device automatically stops energy delivery. As in any energy-based body contouring device, the risk of burn and seroma exist. In one study of the first-generation, pre-FDA approved device, there was a 6.25% incidence of thermal injury and 8.3% minor complication rate (seromas, etc.)¹³ In our current experience of the new generation, FDA-approved device used in approximately 100 operations, we have not seen any complications to date.¹⁴ Conversely, maintaining the temperature and tissue heating at goal ensures efficacy and mitigates the risk of undertreatment. An additional safety feature is that the device continuously monitors the rate of temperature rise so that if a significant temperature increase or spike occurs, energy delivery stops. This feature is called temperature surge protection. From a practical standpoint, the platform gives audio feedback so that the surgeon will know when the temperature is within two degrees of goal by a double time bell signal, as well as when the tissue is heated at goal temperature (triple time bell) and the energy delivery is stopped. This way, the surgeon does not have to look at the screen to know what the temperature is and can maintain his focus on the patient at all times.

ANESTHESIA

Although RFAL may be performed under intravenous sedation or general anesthesia, it is ideally suited for local anesthesia for small, discrete areas in properly selected patients. The operation is performed with excellent analgesia using oral medications such as diazepam, hydrocodone/acetaminophen, and antibiotic safely and comfortably. Irrespective of the mode of anesthesia, the subcutaneous fat space requires tumescent fluid to provide an adequate space in which the instrument travels, as well as the proper turgor of the overlying soft tissues to ensure satisfactory coupling of the external probe to the skin. In addition, the water in the tumescent fluid aids in good RF conductivity and in the internal probe treating at the appropriate depth. For example, adequate tissue turgor is achieved when a sufficient volume of tumescent

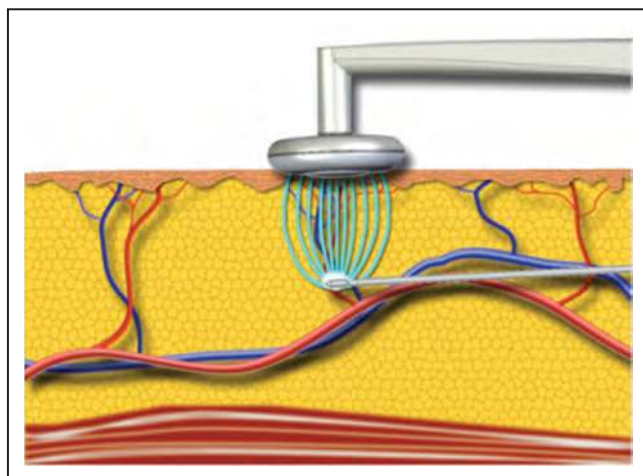


Figure 3. Idealized image of the internal electrode in the subcutaneous adipose layer and the external electrode on the skin depicting radiofrequency energy passing through the soft tissues in between.

solution is injected to result in complete and thorough analgesia. It is important to provide a minimal space of several millimeters between the internal probe and the subdermis to avoid “bad coupling” and impedance mismatches which could result in thermal injury (burn). The high specific heat of water provides a secondary source of heat to the soft tissues as the retained higher temperatures of the tumescent fluid continues to transfer heat long after the application of the RF energy has been completed.

Higher concentrations of lidocaine are required for comfort and an isotonic solution of 1000 mg of lidocaine with sodium bicarbonate (to buffer the acidic pH) and 1.5 cc of 1:1000 concentration for epinephrine is used for tumescent. The American Society of Plastic Surgeons guideline maximum lidocaine load for tumescent liposuction of 35 mg/kg body weight¹⁵ is followed. This results in a well-tolerated procedure with a short recuperative phase (back to daily activities within a day) and an excellent safety profile.¹⁶

APPLICATIONS IN PLASTIC SURGERY

Arms

Arm contouring remains a challenge in our field. Mainly due to the dependent nature of the fat and skin in this anatomical area. Brachioplasty has been our mainstay treatment for this area, when there is laxity not amenable to traditional liposuction surgery. However, the positioning of the scar and the nature of it lends itself to a high visibility problem for many patients and thus not a viable solution. This “gap” in treatment offering has limited arm contouring with brachioplasty to a relatively small number of patients, according to ASAPS statistics approximately 15,000 a year.¹ It has been postulated that energy-assisted

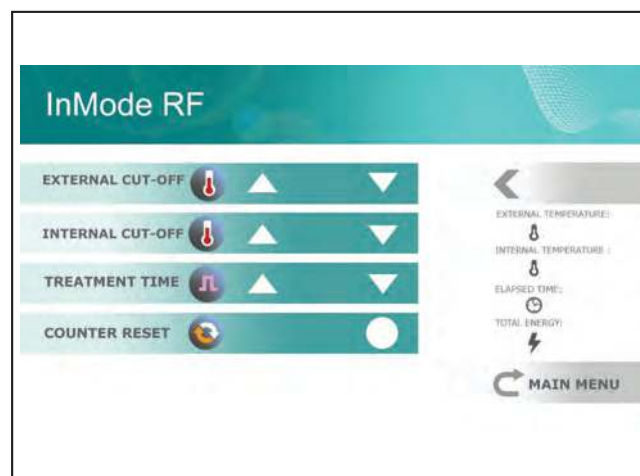

Figure 4. Image of the user-interface screen on the BodyTite generator platform. Note the external and internal cut-off settings and temperature reading outputs.

Table 2. Arm Classification Scheme Identifying Degree of Laxity into Six Categories (types) With Proposed Treatment

	ASL	ASQ	Adiposity	Treatment
Type I	Mild	Good	–	Not RFAL candidate
Type II	Moderate	Good	+	SAL/LAL
Type III	Moderate	Poor	+	RFAL
Type IV	Severe	Good	+	RFAL
Type V	Severe	Poor	+	RFAL + staged skin excision
Type VI	Severe	Poor	–	Brachioplasty

ASL, arm skin laxity; ASQ, arm skin quality; LAL, laser-assisted liposuction; RFAL, radiofrequency-assisted liposuction; SAL, suction-assisted lipectomy.

liposuction of the arm has led to increased contraction when ultrasound energy has been used. In addition, aggressive subdermal liposuction with its claims of skin contraction runs a high risk for contouring defects. RFAL is a new nonexcisional technique that lends itself to superior results in group of patients that we never had a solution for.¹⁷ In order to properly treat these types of patients the authors devised a road map in the form of a new classification scheme¹¹ (Table 2) that takes into account not only skin laxity but also skin quality and amount of adiposity present. When approaching these types of patients the operator has to address the arm like a cylinder or a garment requiring “taking in” for proper redraping. The concept of an internal brachioplasty scar is advanced through a proper amount of energy delivery along the newly coined triceps midline meridian line (TMM) (Figures 5 and 6). The excess scarring along this line serves as a recruitment point for excess redundant tissue just as it would for a brachioplasty. The portion of the arm contributing to arm



Figure 5. Schematic representation of the triceps midline meridian (TMM) concept indicating where most of the radiofrequency energy is deposited in order to cause radial contraction of the arm.

laxity is divided into two zones where the majority of the RF energy is delivered. This is followed by 270° liposuction sparing the area of the bicipital groove where the vessels and nerves lie (“no man’s land”). Once discontinuous undermining is performed via SAL the excess tissue contracts around the “internal brachioplasty” line (ie, TMM leading to redraping of the soft tissue envelope).

Abdomen

The postpartum abdomen presents a series of challenges for plastic surgeons. Ranging from addressing laxity, when to perform liposuction and when to avoid, repairing diastasis recti and so on. One of the most difficult decisions however, to address is the patient that presents with postpartum infraumbilical laxity, no diastasis (or minimal), lack of C-section incision and is not bad enough for an excisional procedure (ie, abdominoplasty). These patients are emphatic in their wishes to not have a scar but complain of skin laxity, especially when they are in the flexed position (pic). These “gap” patients are typically good candidates for RFAL on condition that they have enough adipose tissue to provide an intact FSN for heating and retraction.¹⁸ The ability to effectively treat this particular problem opens the door to a large number of patients that would otherwise never consider any plastic surgery treatment due to their fear of having a scar (Figures 7 and 8).

Medial Thighs

The medial thigh region has always been an area that a lot of patients complain about when visiting their surgeon. The media push about the need to have a “thigh gap” as a

sign of beauty and sexual attractiveness has only exacerbated the request for body contouring in this region. The need to explain to patients the need for a very conservative approach when addressing this area with liposuction has been the standard teaching principal in all training programs around the country. Unfortunately the “thigh gap” is not just related to the amount of fat in the medial thighs but also to the anatomic alignment of the underlying musculoskeletal framework and as such is not necessarily amenable to operative correction. This triangular area that is formed by the medial thigh adipose tissue and buttock confluence has led many a surgeon astray with dismal results when trying to achieve. In simple terms it is the “Bermuda Triangle” of lower extremity liposuction. The reason behind this fact, is that the medial thigh region is an area of nonadherence and as such it’s at high risk not only for residual iatrogenic laxity but also for contour deformity. The correction for over resection in best of cases is with autologous fat grafting and in worst of cases a medial thigh lift. The resulting scar is not acceptable in any case and the main reason why patients with medial thigh laxity avoid seeing a plastic surgeon or do not proceed with surgery. RFAL when used judiciously in this area, in the right patient, can allow the operator to be more aggressive with the fat resection. The reason being is that the heat generated by the RF platform will allow greater retraction of the soft tissue envelope and address the laxity that tends to plague this anatomical area.

Neck

The anterior neck and jawline are also amenable to contouring by fat removal and skin tightening with RFAL in that

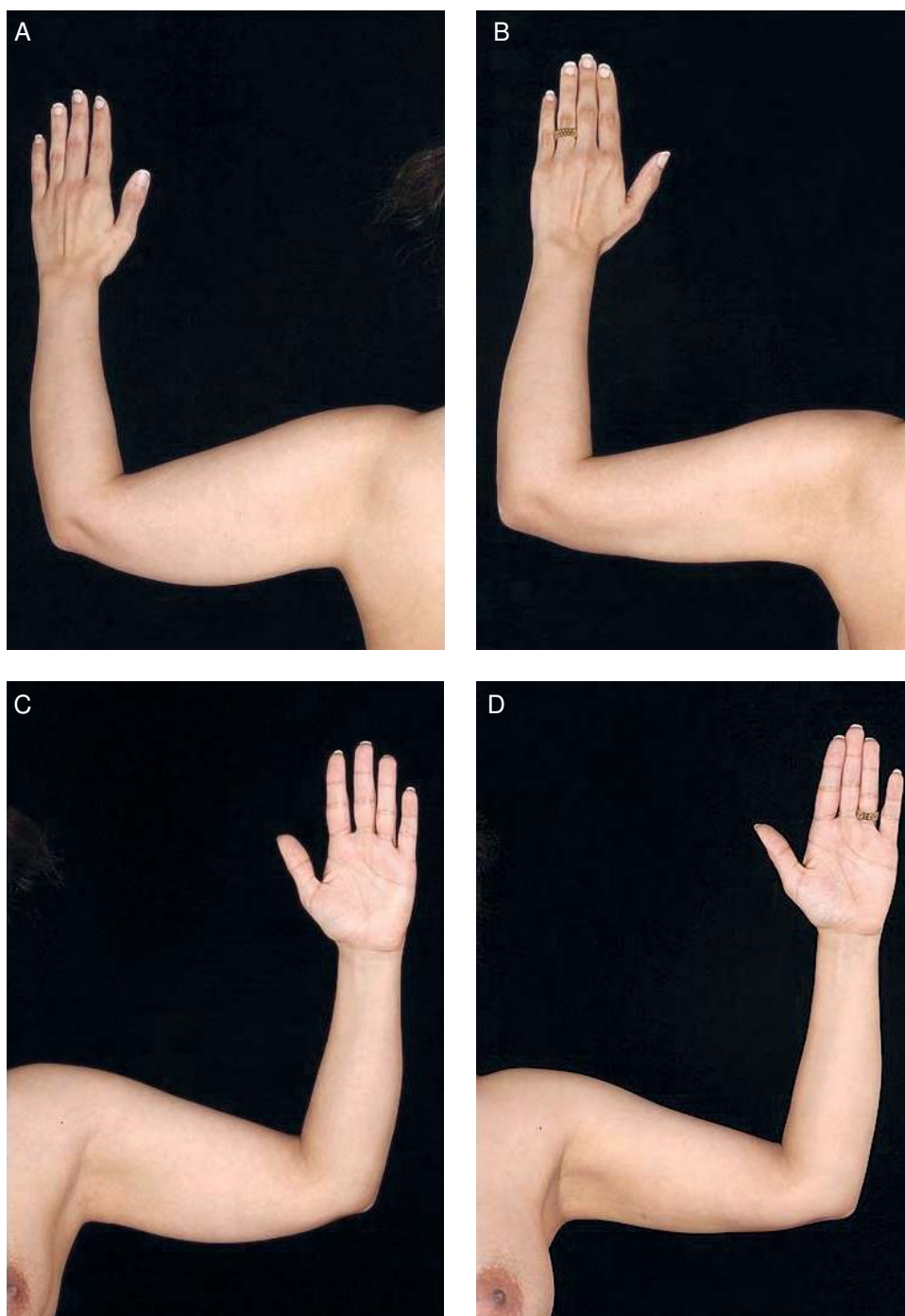


Figure 6. A 40-year-old woman with Type IV arm. External temperature 42°C. (A, C) Preoperative and (B, D) 12 month postoperative photographs.

the submental angle presents a challenge for the redrawing of the soft tissue coverings following liposuction.¹⁹ Due to the acuteness of the angle, it can be prone to poor aesthetic outcomes if the support of the overlying skin is inadequate despite maneuvers otherwise such as inflammation due to manual suction, laser energy, or ultrasonic energy. With the deposition of RF energy, the relatively thin skin and

soft tissue must be accounted for with lower goal temperature settings. In addition, the subcutaneous space is also preplatysmal superficial to the muscle and, therefore, the superficial fascial system. The recruitment of soft tissues in the neck are more limited in other areas of the body which also adds to the difficulties in eliciting enough contraction to obtain a satisfactory submental angle.

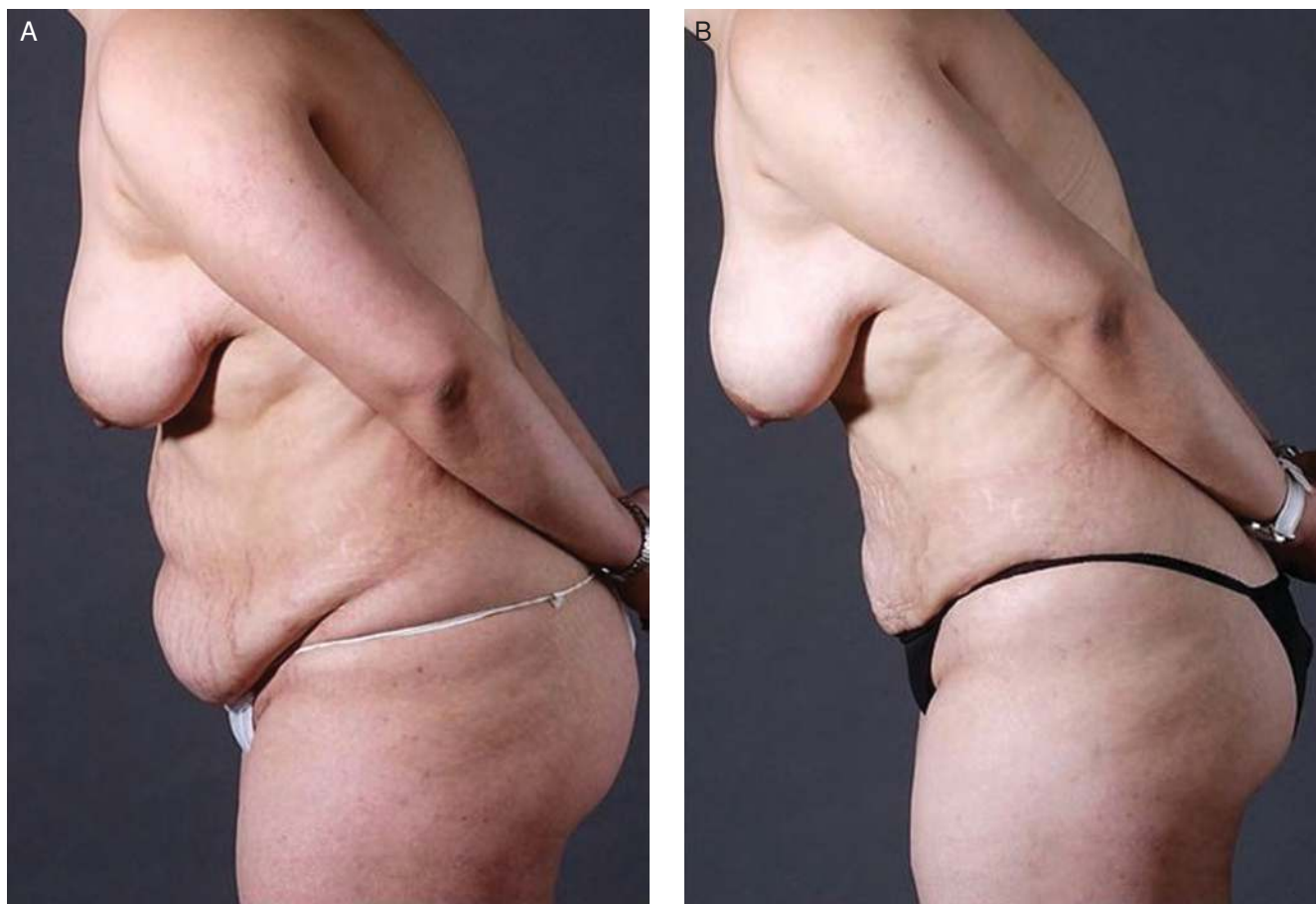

Figure 7. A 38-year-old, gravida 3 woman, with significant abdominal wall and skin laxity and refused abdominoplasty. (A) Preoperative and (B) 12 month postoperative photographs. A total of 2300 mL lipoaspirate was removed; external temperature, 42°C.

Anatomical landmarks for the areas of treatment include the anterior border of the sternocleidomastoid muscle laterally on both sides which demarcates the posterior extent of the treatment zone. Superiorly, the inferior border of the mandible is noted. It is not necessary to go above the mandible where the marginal mandibular nerve typically travels. The first cervical crease demarcates the inferior extent of dissection. The midline is marked in line with the central incisors and the fat excess topographically marked in the customary fashion for liposuction. Three access incisions are made with a 14-gauge needle for a circular puncture: one in the midline submental crease and one behind each lobe. Approximately 250 to 300 mL of tumescent fluid is injected providing analgesia and vasoconstriction. Next, the NeckTite device is used to heat the soft tissues with typical goal temperatures of 36°C externally and 55°C internally for 15 to 30 sec per site. Small cannula liposuction is then performed to remove the heated fluids and fat for contouring. Nylon sutures 5-0 are used to close the access incisions and the patient is covered with hydrating

gel and a compression bandage. Sutures are removed at about one week postoperatively.

Other Applications

Due to the considerable soft tissue matrix contraction elicited by the RF device, indications of its use include mastopexy where there is no skin excision.²⁰ Via standard access incisions, strategically applied RF energy to the breast can cause contraction of the superior pole of the breast. This will, in effect, vertically raise the nipple-areola complex (NAC). This effect can be a possible application for moderate to mild ptosis (Grade I, Grade II) and early results have been encouraging. Regarding the inferior pole of the breast, the midline soft tissue can be contracted with RF energy to shorten the transverse length in order to reduce skin excess in that vector. Conversely, in the male chest where volume is reduced in gynecomastia cases (Figure 9), RF energy is applied in order to prevent superior rotation of the NAC as well as contract the inferior pole skin where the fat and breast tissue is removed.

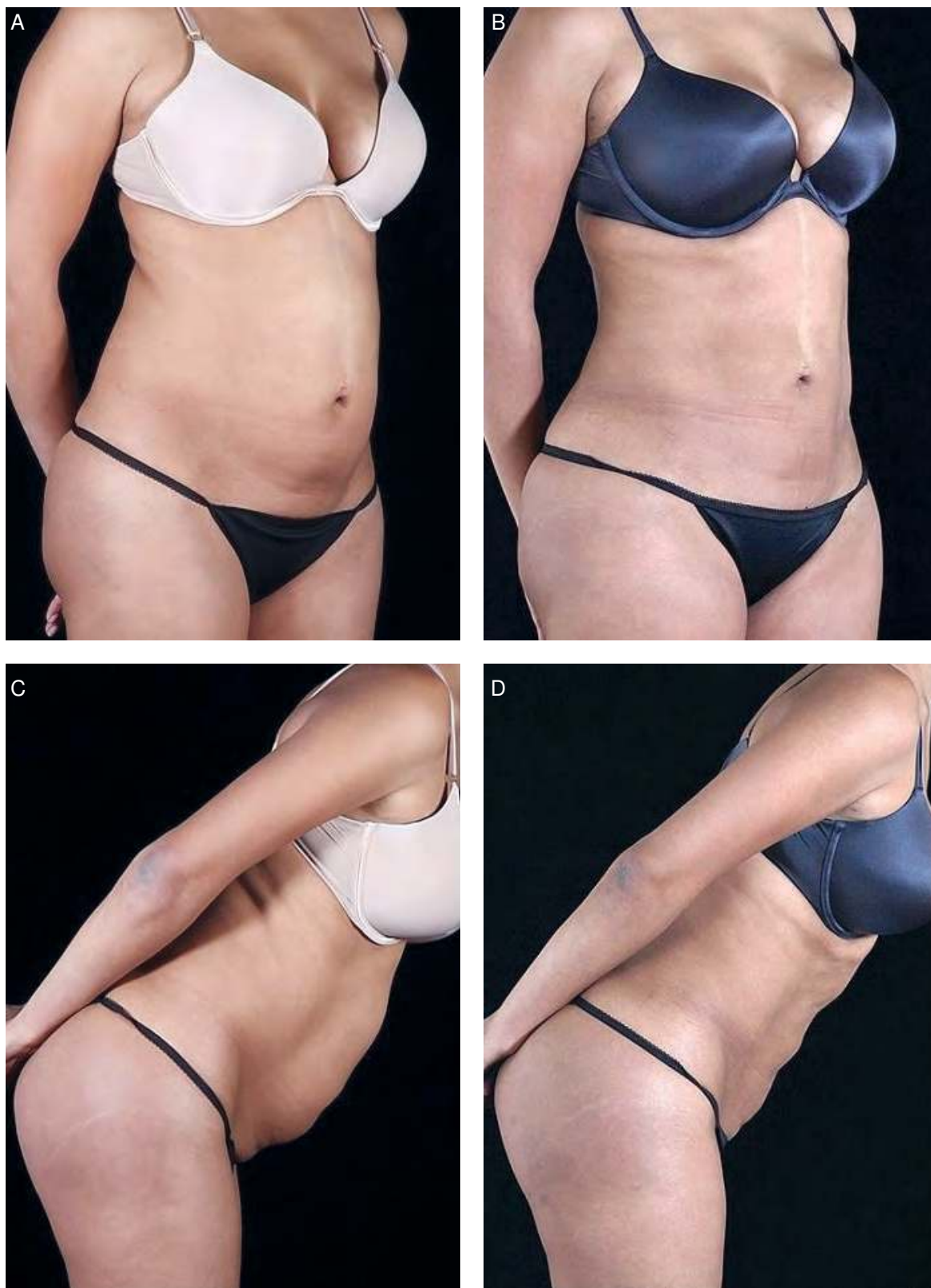


Figure 8. A 35-year-old, gravida 2 woman with no significant diastasis. (A, C) Preoperative and (B, D) 12 month postoperative photographs. A total of 1000 mL lipoaspirate was removed; external temperature, 40°C.

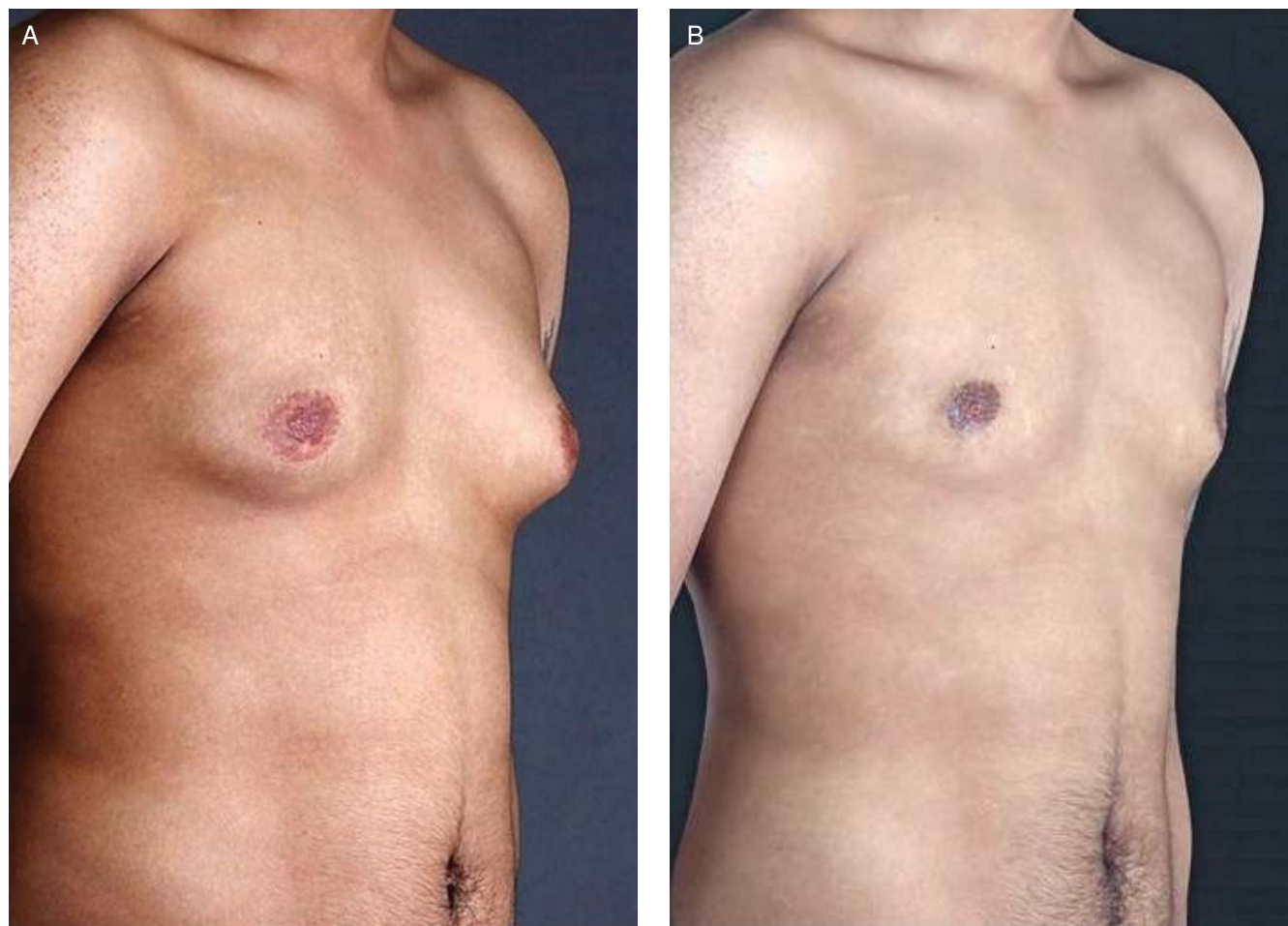

Figure 9. A 28-year-old man with gynecomastia treated with radiofrequency-assisted liposuction (RFAL). (A) Preoperative and (B) 12 month postoperative photographs. Target temperature of 42°C was achieved, and 500 mL lipoaspirate was removed bilaterally in total.

DISCUSSION

With increasing popularity and easy access to body contouring procedures, the indications of liposuction are expanding to include both younger and older patients. It's important to delineate the following when discussing this type of technology. The ability to produce a mediocre result without a scar might be better than a perfect result with a scar. This is in line with the limitations of the device that present in cases such as massive weight loss patients who have irreversibly damaged dermal and fibro-septal network and/or patients advanced in age. It's true that the gold standard for face laxity is a facelift and for abdominal laxity it's an abdominoplasty etc. However, having the ability to treat a large segment of the population that could be borderline patients (most of whom would be turned down) is a fact that should not be easily dismissed. Those with borderline elasticity (treatment gap patients) of the overlying soft tissue present challenges in obtaining reliable, safe, and reproducible aesthetic outcomes. The reason being that proper uniform skin retraction is not reliable

once the fat has been removed. Previous energy-based devices with purported soft tissue retraction claims have failed to produce significant results.

CONCLUSION

RFAL presents a novel application of electromagnetic energy in a unique delivery device that ensures both uniform and efficient heating of the soft tissues to target temperatures while including multiple safety parameters to greatly mitigate the risk of overheating and burns. The cost of acquiring the device (like any technology platform) should always be weighed against the ability to not only attract new patients but also to provide or enhance consistently good results (Table 3). This has been the case in the authors' experience with this device where a patient satisfaction survey following RFAL indicated that 89% of patients who underwent the procedure would recommend it. In addition, an independent plastic surgeon evaluation of the results was consistently positive.¹³ Coupled with judicious patient selection and good body contouring, RFAL has the potential to

Table 3. Financial Considerations

Simple economic model (financial assumptions)	
Device cost	205,000 USD
Disposable cost	200 USD
Down payment	40,000 USD
Lease rate	5%
Lease term	36 months
Cash revenue	7000 USD
Cases/month	1
Cash on cash returns analysis (financial assumptions)	
Patient revenue	7000 USD
Disposable	200 USD
Lease payment/month	4925 USD
Profit	1875 USD

elicit a 3-dimensional soft tissue contraction reliably and predictably to both expand the base of otherwise not traditional liposuction candidates, as well as improve outcomes in patients for whom liposuction is an option. We believe that RFAL technology has the potential to deliver both.

Disclosures

Drs Theodorou and Chia are shareholders in the InMode Corporation. Dr Del Vecchio is a co-founder and co-owner of Surgistem Technology, LLC.

Funding

This article was supported by the InMode Corporation (Toronto, Canada), who co-funded the development of this supplement.

REFERENCES

1. Cosmetic surgery national data bank statistics. *Aesthet Surg J*. 2017;37(suppl 2):1-29.
2. Galuppo MM. Millennials expected to take over 25,000 selfies in their lifetime. <https://www.aol.com/article/news/2017/05/19/millennials-expected-to-take-over-25-000-selfies-in-their-lifetime/22099995>. Accessed January 31, 2018.
3. Chia CT, Neinstein RM, Theodorou SJ. Evidence-based medicine: liposuction. *Plast Reconstr Surg*. 2017;139(1):267e-274e.
4. Teruya TH, Ballard JL. New approaches for the treatment of varicose veins. *Surg Clin North Am*. 2004;84(5):1397-417, viii.
5. Paul M, Mulholland RS. A new approach for adipose tissue treatment and body contouring using radiofrequency-assisted liposuction. *Aesthetic Plast Surg*. 2009;33(5):687-694.
6. DiBernardo BE, Reyes J, Chen B. Evaluation of tissue thermal effects from 1064/1320-nm laser-assisted lipolysis and its clinical implications. *J Cosmet Laser Ther*. 2009;11(2):62-69.
7. Rohrich RJ, Beran SJ, Kenkel JM, Adams WP Jr, DiSpaltro F. Extending the role of liposuction in body contouring with ultrasound-assisted liposuction. *Plast Reconstr Surg*. 1998;101(4):1090-1102; discussion 1117.
8. Sasaki GH. Quantification of human abdominal tissue tightening and contraction after component treatments with 1064-nm/1320-nm laser-assisted lipolysis: clinical implications. *Aesthet Surg J*. 2010;30(2):239-245.
9. Paul M, Blugerman G, Kreindel M, Mulholland RS. Three-dimensional radiofrequency tissue tightening: a proposed mechanism and applications for body contouring. *Aesthetic Plast Surg*. 2011;35(1):87-95.
10. Rohrich RJ, Smith PD, Marcantonio DR, Kenkel JM. The zones of adherence: role in minimizing and preventing contour deformities in liposuction. *Plast Reconstr Surg*. 2001;107(6):1562-1569.
11. Chia CT, Theodorou SJ, Hoyos AE, Pitman GH. Radiofrequency-assisted liposuction compared with aggressive superficial, subdermal liposuction of the arms: a bilateral quantitative comparison. *Plast Reconstr Surg Glob Open*. 2015;3(7):e459.
12. Kim YH, Cha SM, Naidu S, Hwang WJ. Analysis of postoperative complications for superficial liposuction: a review of 2398 cases. *Plast Reconstr Surg*. 2011;127(2):863-871.
13. Theodorou SJ, Paresi RJ, Chia CT. Radiofrequency-assisted liposuction device for body contouring: 97 patients under local anesthesia. *Aesthetic Plast Surg*. 2012;36(4):767-779.
14. Ulvila D, Chia CT, Theodorou SJ. Radiofrequency-assisted liposuction: experience with generation II RFAL device a safety and efficacy study. Presented at the ASMLS Annual Conference 2018 in Dallas, TX; April 2018.
15. American Society of Plastic Surgeons Committee on Patient Safety. *Practice Advisory on Liposuction: Executive Summary*. <https://www.plasticsurgery.org/documents/medical-professionals/health-policy/key-issues/Executive-Summary-on-Liposuction.pdf>. Accessed January 31, 2018.
16. Chia CT, Albert MG, Del Vecchio S, Theodorou SJ. 1000 consecutive cases of laser-assisted liposuction utilizing the 1440 nm wavelength Nd:YAG laser: assessing the safety and efficacy. *Aesthetic Plast Surg*. 2018;42(1):9-12.
17. Duncan DI. Improving outcomes in upper arm liposuction: adding radiofrequency-assisted liposuction to induce skin contraction. *Aesthet Surg J*. 2012;32(1):84-95.
18. Duncan DI. Nonexcisional tissue tightening: creating skin surface area reduction during abdominal liposuction by adding radiofrequency heating. *Aesthet Surg J*. 2013;33(8):1154-1166.
19. Keramidis E, Rodopoulou S. Radiofrequency-assisted liposuction for neck and lower face adipodermal remodeling and contouring. *Plast Reconstr Surg Glob Open*. 2016;4(8):e850.
20. Duncan DI. *Scarless scalpel free breast lifting advantages and limitations*. <http://prime-journal.com/scarless-scalpel-free-breast-lifting-advantages-and-limitations>. Accessed January 31, 2018.